

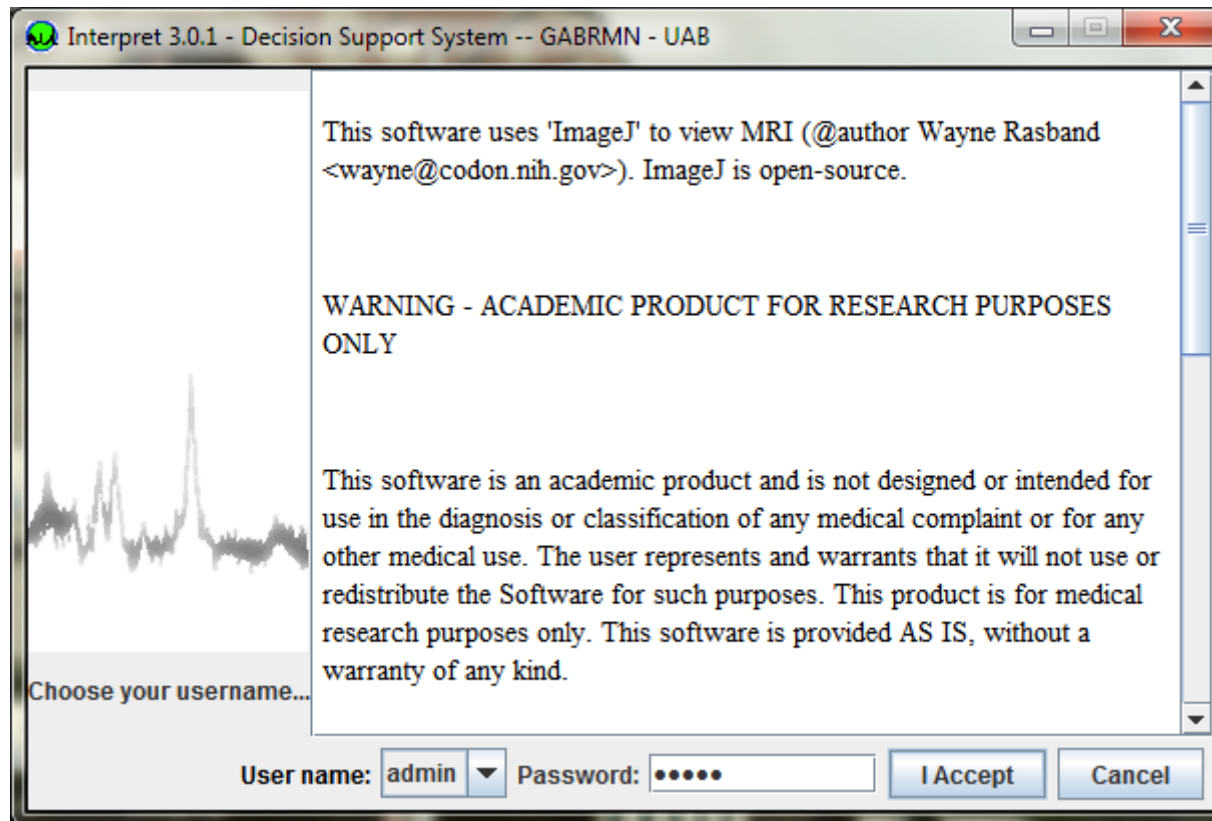
How to evaluate a case with the **INTERPRET DSS 3.0**

and SV MRS data from human brain
tumours at 1.5 T

- A radiologist comes to us with the spectrum of an abnormal brain mass.
- The clinical presentation and the MRI shows reasonable suspicion that the abnormal mass can be either a low-grade glial tumor or a pseudotumoral mass (infarct, multiple sclerosis, abscess, etc).

How do you evaluate the spectra of
the case with the INTERPRET DSS?

Double-click the DSS 3.0.2 icon on your desktop



Enter the password and click accept

Menu where the classification problem is shown, here the "most common tumour types" with short TE spectra option selected

The main screen is displayed on your desktop

Latent space of cases

Classifier classes Available Tissues Cases Set

<input checked="" type="checkbox"/> Low Grade	<input checked="" type="checkbox"/> Astrocytoma 2	<input checked="" type="checkbox"/> Oligoastrocytoma	<input checked="" type="checkbox"/> Oligodendroglioma
<input checked="" type="checkbox"/> Aggressive	<input checked="" type="checkbox"/> Glioblastoma	<input checked="" type="checkbox"/> Metastasis	
<input checked="" type="checkbox"/> Meningioma	<input checked="" type="checkbox"/> Meningioma		

Classes of the classification problem

MR Spectra MR Images Clinical Record Case Notes

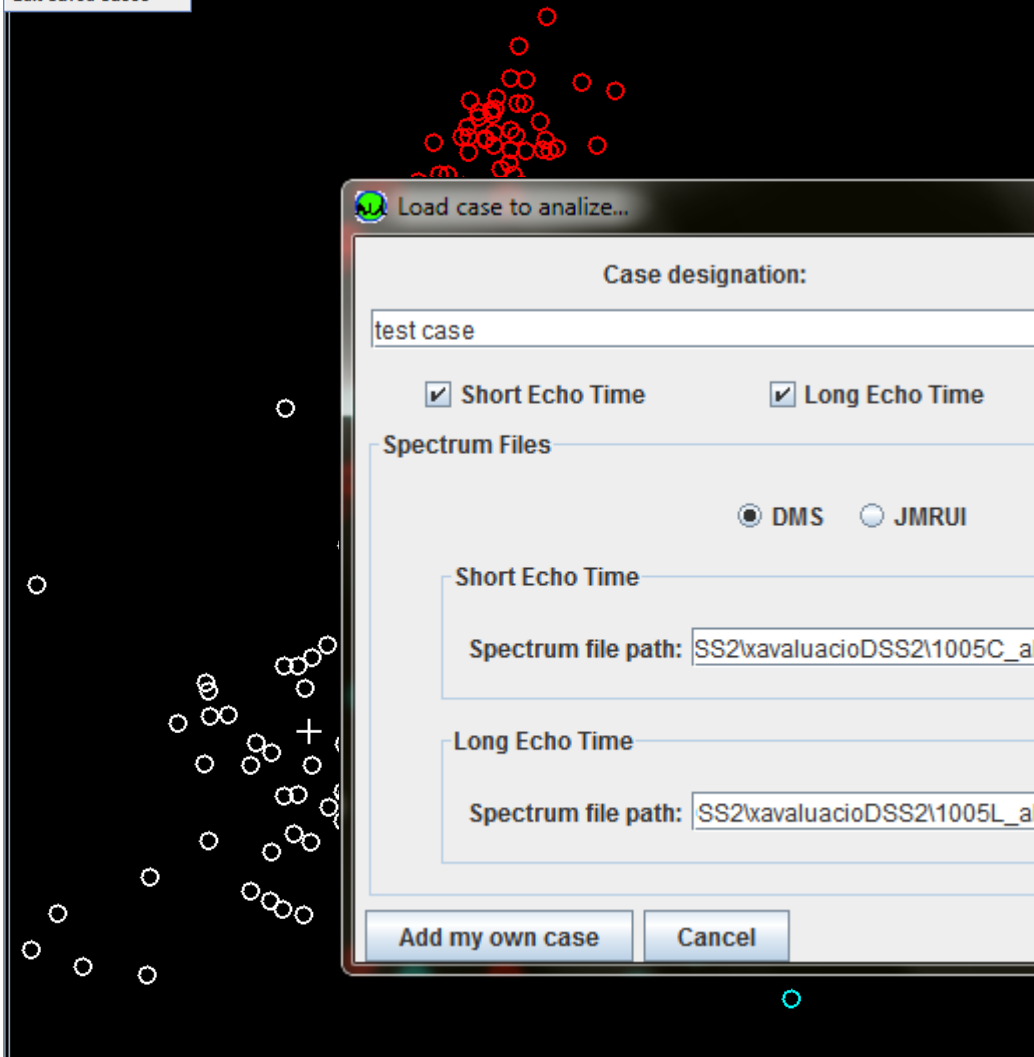
ID: no case selected Pathology:

No Overlay Show Voxel Image Show other MRS

7.0 6.0 5.0 4.0 3.0 2.0 1.0 0.0 -1.0 -2.0

st common tumour types, short TE

Visual Overview of Case Database



ID: no case selected Pathology:

MR Spectra MR Images Clinical Record Case Notes

No Overlay Show Voxel Image Show other MRS

2.0 1.0 0.0 -1.0 -2.0

Load case to analyze...

Case designation: test case

Short Echo Time Long Echo Time

Origin
 Raw (time)
 Processed (freq)

Spectrum Files
 DMS JMRUI

Short Echo Time
Spectrum file path: SS2\avaluacioDSS2\1005C_aligned.art

Long Echo Time
Spectrum file path: SS2\avaluacioDSS2\1005L_aligned.art

Add my own case Cancel

Classifier classes Available Tissues Cases Set

<input checked="" type="checkbox"/> Low Grade	<input checked="" type="checkbox"/> Astrocytoma 2	<input checked="" type="checkbox"/> Oligoastrocytoma	<input checked="" type="checkbox"/> Oligodendroglioma
<input checked="" type="checkbox"/> Aggressive	<input checked="" type="checkbox"/> Glioblastoma	<input checked="" type="checkbox"/> Metastasis	
<input checked="" type="checkbox"/> Meningioma	<input checked="" type="checkbox"/> Meningioma		

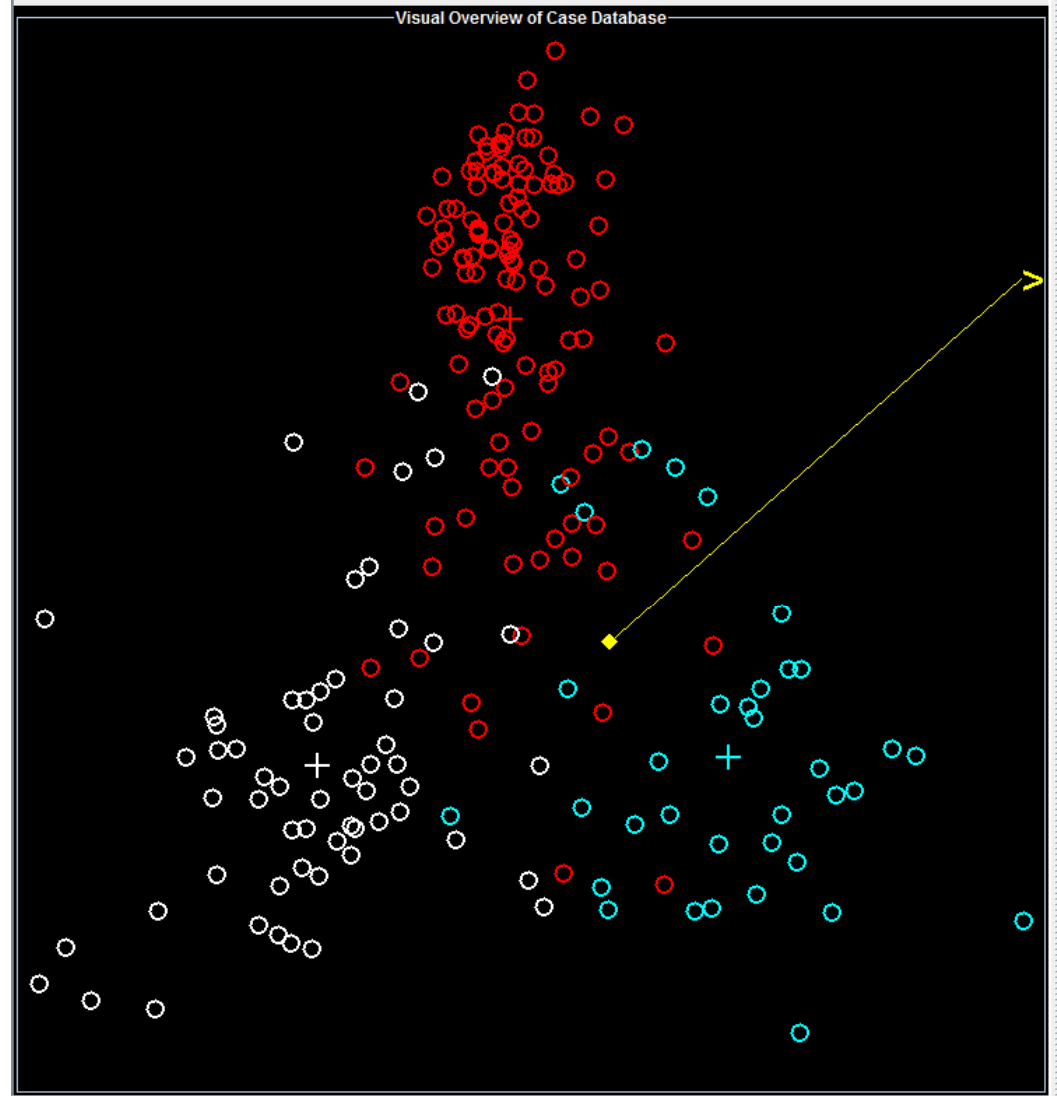
7.0 6.0 5.0 4.0 3.0 2.0 1.0 0.0 -1.0 -2.0

No Overlay Show Voxel Image Show other MRS

MR Spectra MR Images Clinical Record Case Notes

ID: no case selected Pathology:

Classif: Most common tumour types, short TE

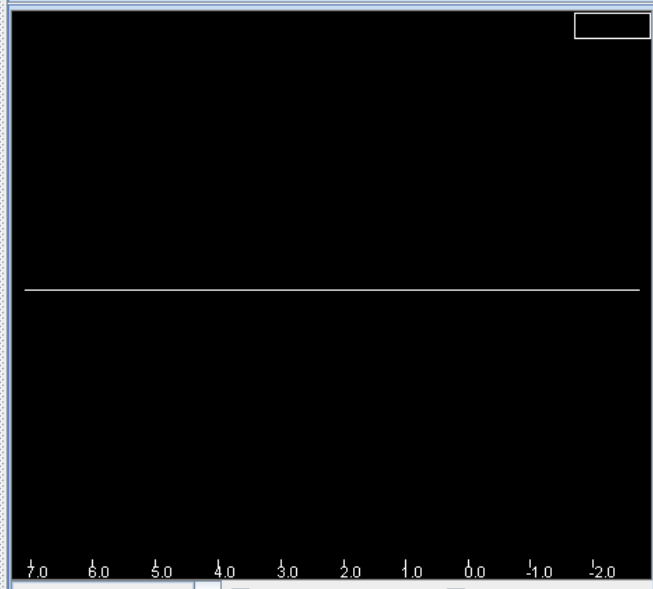
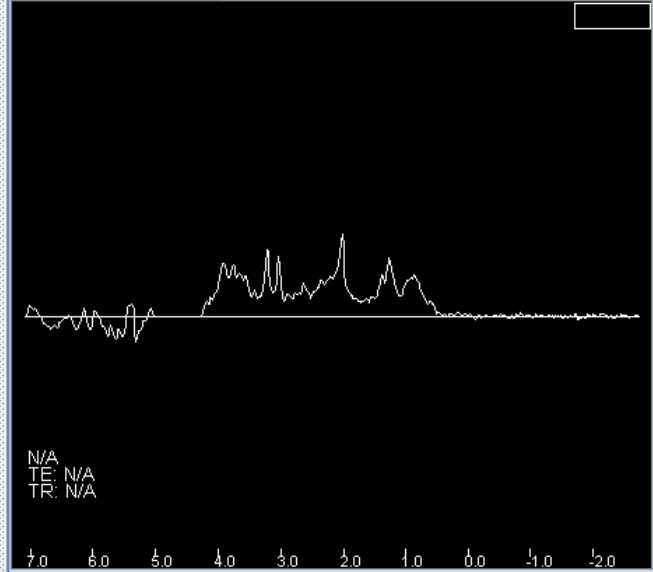


Classifier classes	Available Tissues	Cases Set	
<input checked="" type="checkbox"/> Low Grade	<input checked="" type="checkbox"/> Astrocytoma 2	<input checked="" type="checkbox"/> Oligoastrocytoma	<input checked="" type="checkbox"/> Oligodendroglioma
<input checked="" type="checkbox"/> Aggressive	<input checked="" type="checkbox"/> Glioblastoma	<input checked="" type="checkbox"/> Metastasis	
<input checked="" type="checkbox"/> Meningioma	<input checked="" type="checkbox"/> Meningioma		

ID: test case Pathology: userCase

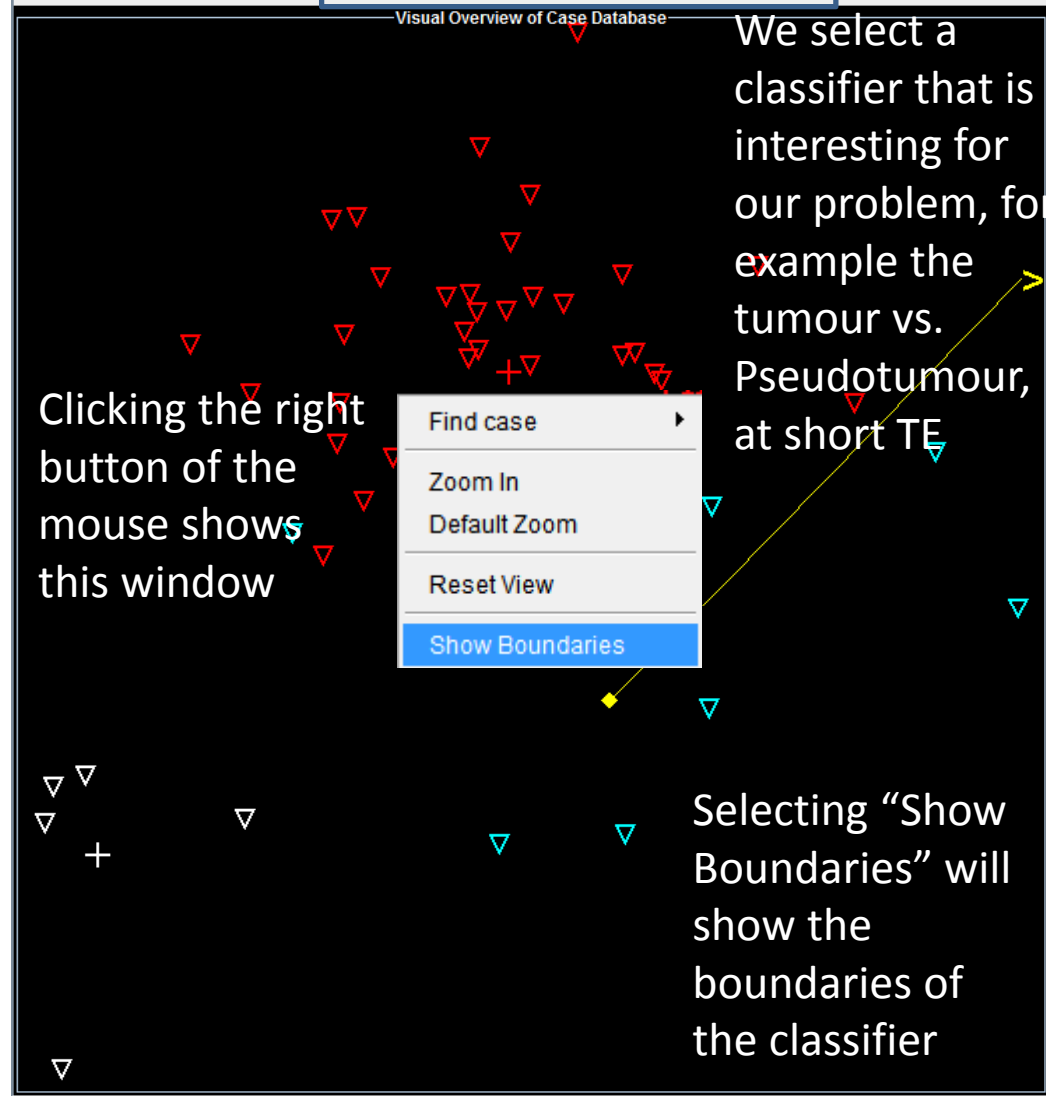
MR Spectra MR Images Clinical Record Case Notes

No Overlay Show Voxel Image Show other MRS



MR Spectra MR Images Clinical Record Case Notes

ID: no case selected Pathology:



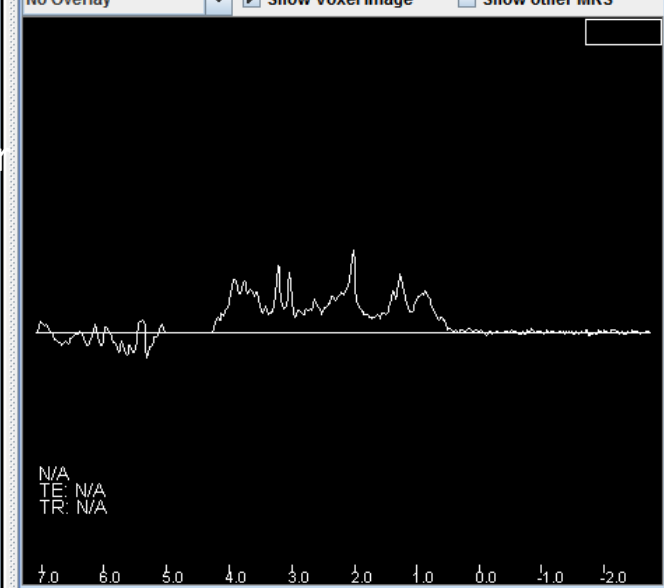
Clicking the right button of the mouse shows this window

We select a classifier that is interesting for our problem, for example the tumour vs. Pseudotumour, at short TE

Selecting "Show Boundaries" will show the boundaries of the classifier

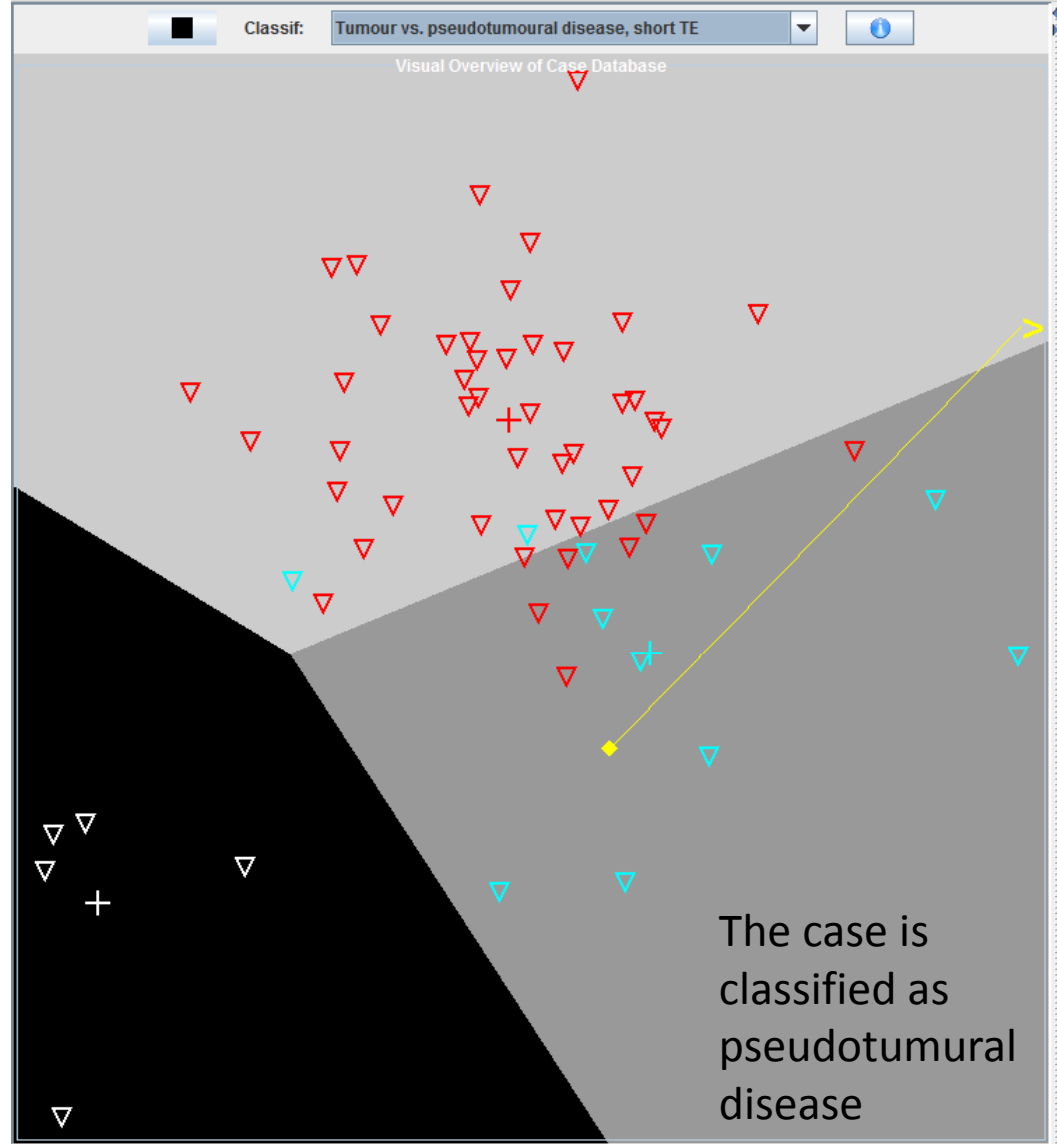
Classifier classes Available Tissues Cases Set

<input checked="" type="checkbox"/> Pseudotumoural Disease	<input checked="" type="checkbox"/> Abscess	<input checked="" type="checkbox"/> Multiple scl...	<input checked="" type="checkbox"/> Infarct	<input checked="" type="checkbox"/> Reactive as...	
<input checked="" type="checkbox"/> Tumour	<input checked="" type="checkbox"/> Astrocytom...	<input checked="" type="checkbox"/> Oligodendr...	<input checked="" type="checkbox"/> Oligoastroc...	<input checked="" type="checkbox"/> Astrocytom...	<input checked="" type="checkbox"/> Oligoastroc...
<input checked="" type="checkbox"/> Normal Brain Tissue	<input checked="" type="checkbox"/> Normal Tis...				

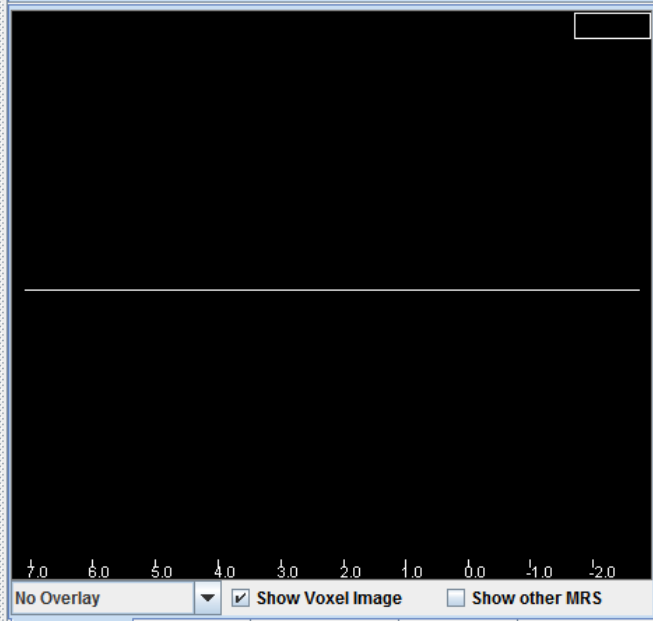
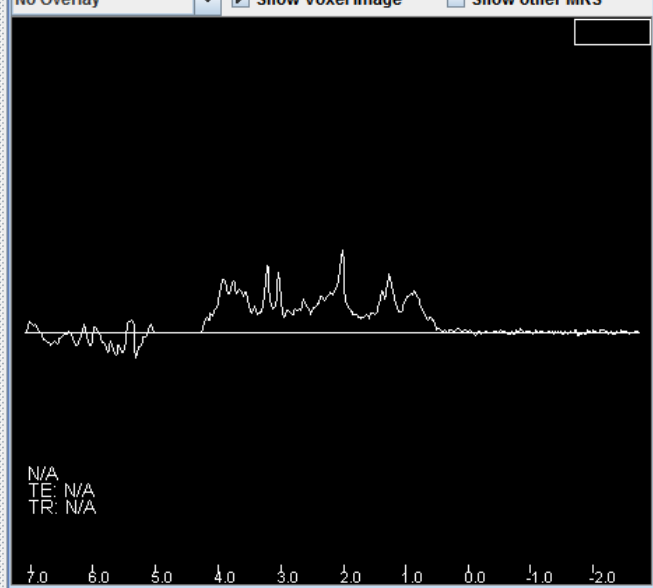


MR Spectra MR Images Clinical Record Case Notes

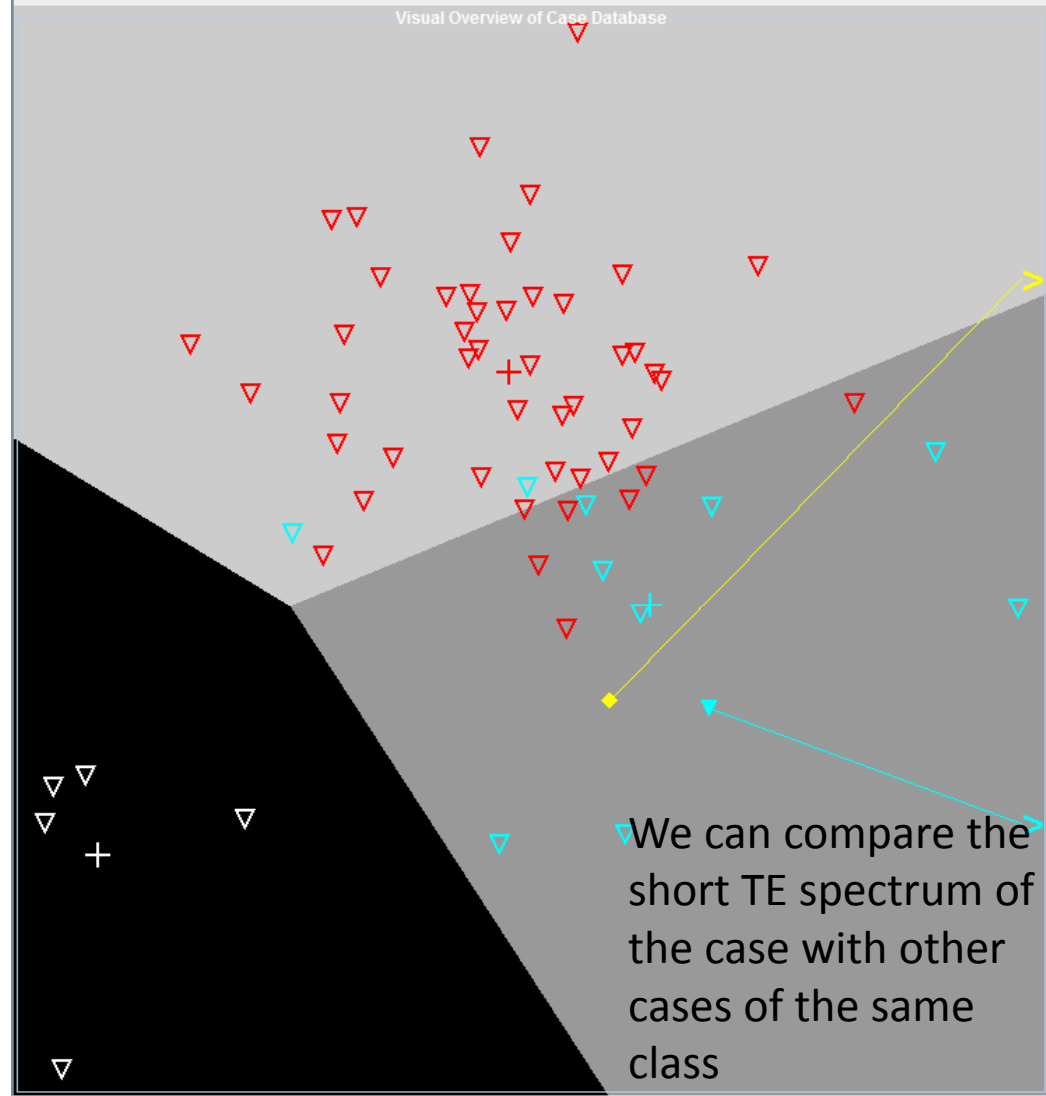
ID: no case selected Pathology:



Classifier classes	Available Tissues	Cases Set
<input checked="" type="checkbox"/> Pseudotumoural Disease	<input checked="" type="checkbox"/> Abscess	<input checked="" type="checkbox"/> Multiple scl... <input checked="" type="checkbox"/> Infarct <input checked="" type="checkbox"/> Reactive as...
<input checked="" type="checkbox"/> Tumour	<input checked="" type="checkbox"/> Astrocytom...	<input checked="" type="checkbox"/> Oligodendr... <input checked="" type="checkbox"/> Oligoastroc... <input checked="" type="checkbox"/> Astrocytom... <input checked="" type="checkbox"/> Oligoastroc...
<input checked="" type="checkbox"/> Normal Brain Tissue	<input checked="" type="checkbox"/> Normal Tis...	



Classif: Tumour vs. pseudotumoural disease, short TE

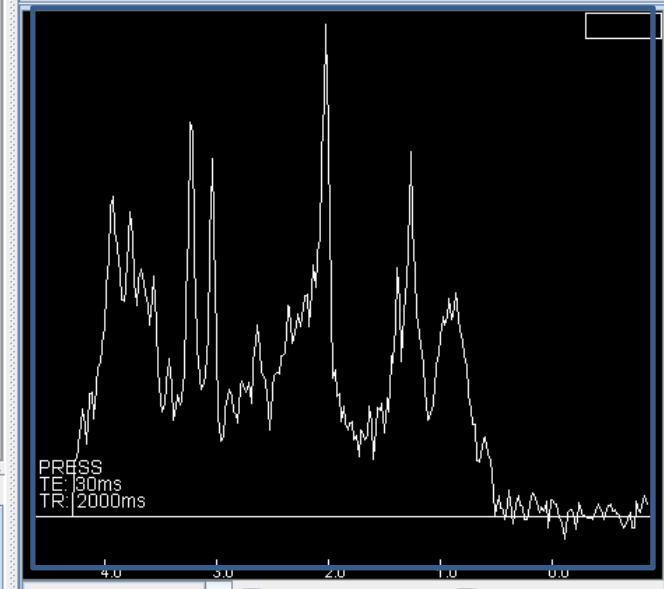
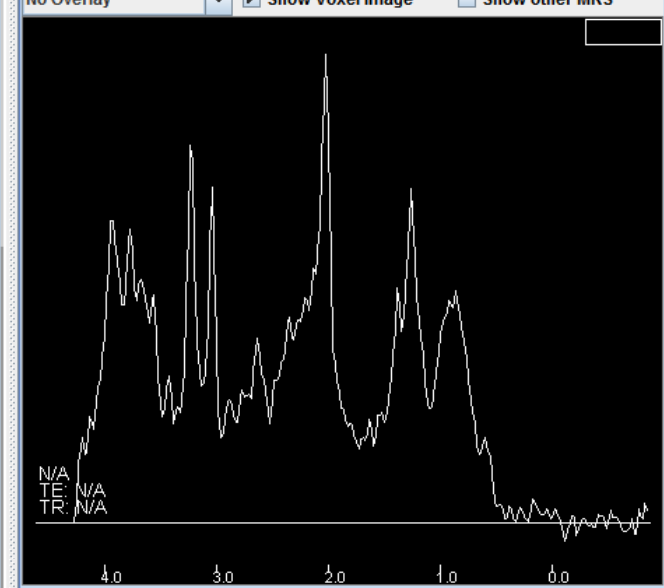


Classifier classes Available Tissues Cases Set

<input checked="" type="checkbox"/> Pseudotumoural Disease	<input checked="" type="checkbox"/> Abscess	<input checked="" type="checkbox"/> Multiple scl...	<input checked="" type="checkbox"/> Infarct	<input checked="" type="checkbox"/> Reactive as...	
<input checked="" type="checkbox"/> Tumour	<input checked="" type="checkbox"/> Astrocytom...	<input checked="" type="checkbox"/> Oligodendr...	<input checked="" type="checkbox"/> Oligoastroc...	<input checked="" type="checkbox"/> Astrocytom...	<input checked="" type="checkbox"/> Oligoastroc...
<input checked="" type="checkbox"/> Normal Brain Tissue	<input checked="" type="checkbox"/> Normal Tis...				


ID: test case Pathology: userCase

MR Spectra MR Images Clinical Record Case Notes



MR Spectra MR Images Clinical Record Case Notes

ID: IDI007 Pathology: Multiple sclerosis



Classifier classes Available Tissues Cases Set

<input checked="" type="checkbox"/> Pseudotumoural Disease	<input checked="" type="checkbox"/> Abscess	<input checked="" type="checkbox"/> Multiple scl...	<input checked="" type="checkbox"/> Infarct	<input checked="" type="checkbox"/> Reactive as...	
<input checked="" type="checkbox"/> Tumour	<input checked="" type="checkbox"/> Astrocytom...	<input checked="" type="checkbox"/> Oligodendr...	<input checked="" type="checkbox"/> Oligoastroc...	<input checked="" type="checkbox"/> Astrocytom...	<input checked="" type="checkbox"/> Oligoastroc...
<input checked="" type="checkbox"/> Normal Brain Tissue	<input checked="" type="checkbox"/> Normal Tis...				

ID: test case Pathology: userCase

MR Spectra MR Images Clinical Record Case Notes

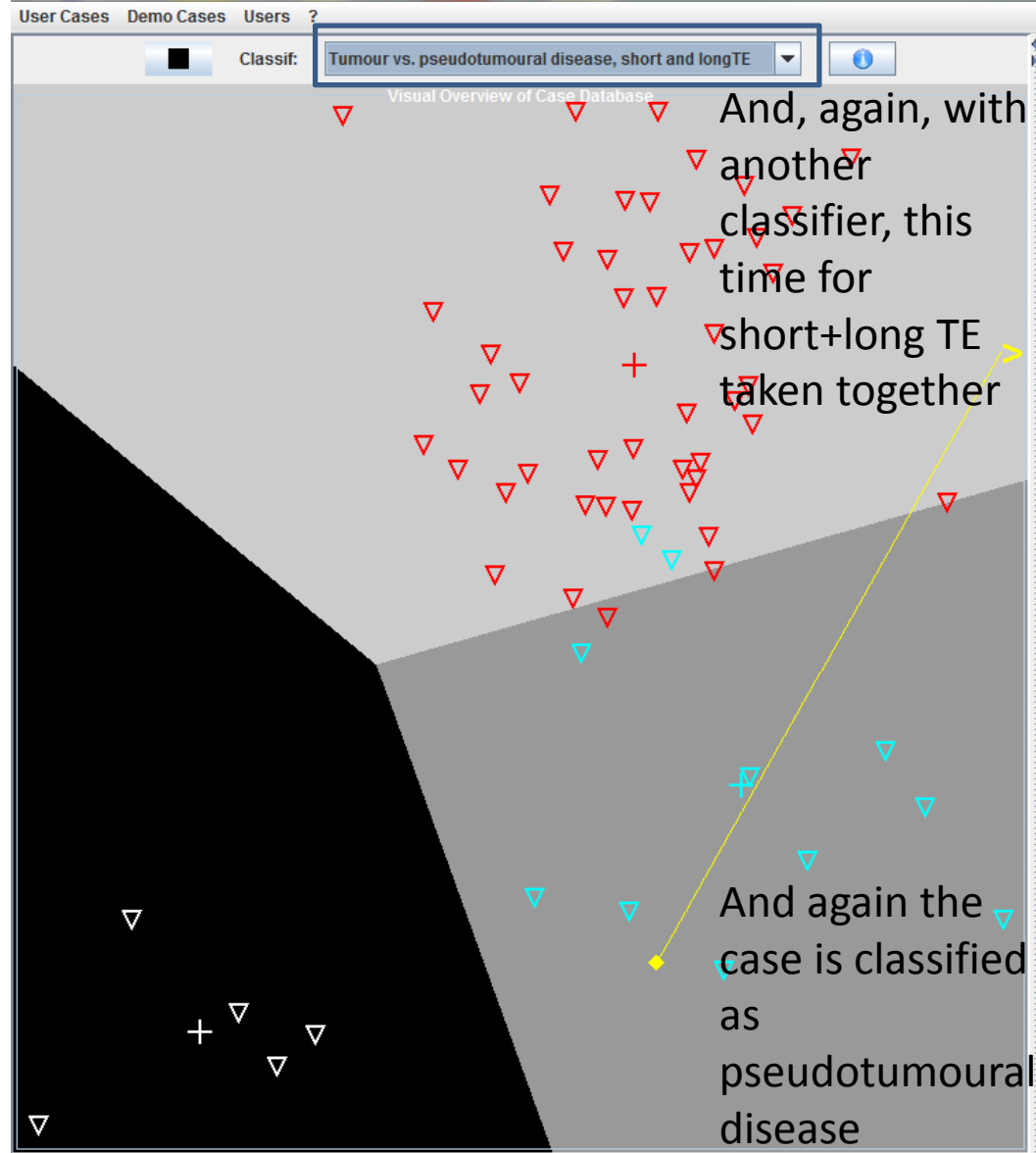
No Overlay Show Voxel Image Show other MRS

4.0 3.0 2.0 1.0 0.0

No Overlay Show Voxel Image Show other MRS

MR Spectra MR Images Clinical Record Case Notes

ID: No case selected Pathology:



Classifier classes Available Tissues Cases Set

<input checked="" type="checkbox"/> Pseudotumoural Disease	<input checked="" type="checkbox"/> Abscess	<input checked="" type="checkbox"/> Multiple scl...	<input checked="" type="checkbox"/> Infarct	<input checked="" type="checkbox"/> Reactive as...	
<input checked="" type="checkbox"/> Tumour	<input checked="" type="checkbox"/> Astrocytom...	<input checked="" type="checkbox"/> Oligodendr...	<input checked="" type="checkbox"/> Oligoastroc...	<input checked="" type="checkbox"/> Astrocytom...	<input checked="" type="checkbox"/> Oligoastroc...
<input checked="" type="checkbox"/> Normal Brain Tissue	<input checked="" type="checkbox"/> Normal Tis...				

ID: test case Pathology: userCase

MR Spectra MR Images Clinical Record Case Notes

No Overlay Show Voxel Image Show other MRS

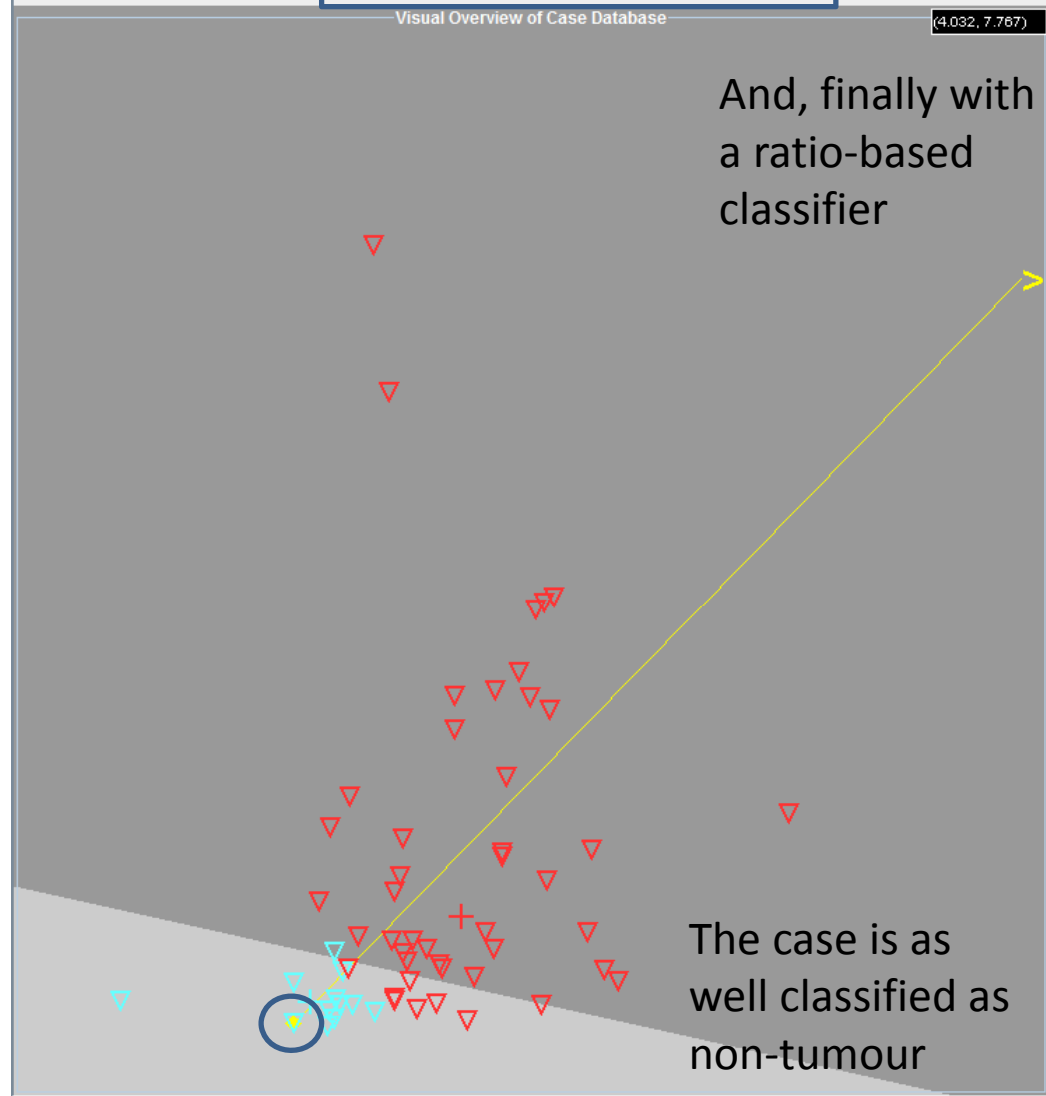
N/A
TE: N/A
TR: N/A

4.0 3.0 2.0 1.0 0.0

No Overlay Show Voxel Image Show other MRS

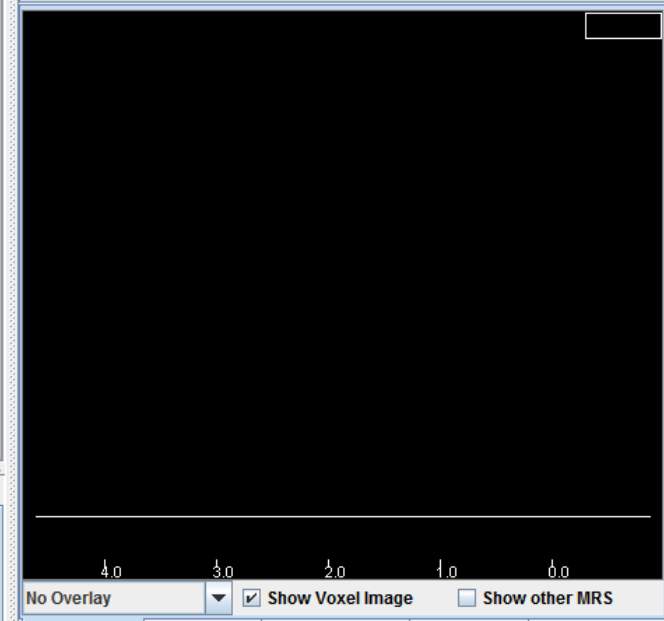
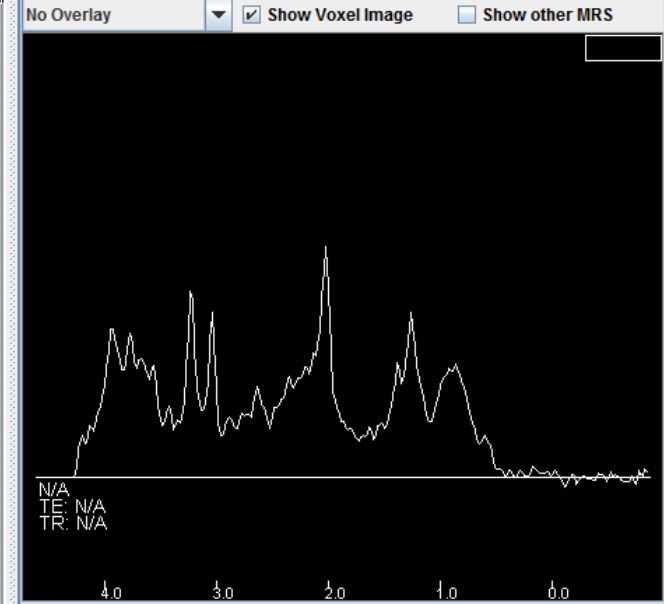
MR Spectra MR Images Clinical Record Case Notes

ID: No case selected Pathology:



Classifier classes Available Tissues Cases Set

<input checked="" type="checkbox"/> Tumour	<input checked="" type="checkbox"/> Astrocytoma 2	<input checked="" type="checkbox"/> Astrocytoma 3	<input checked="" type="checkbox"/> Oligoastrocyt...	<input checked="" type="checkbox"/> Oligoastrocyt...	<input checked="" type="checkbox"/> Oligodendrogl...
<input checked="" type="checkbox"/> Non Tumour	<input checked="" type="checkbox"/> Infarct	<input checked="" type="checkbox"/> Multiple scler...	<input checked="" type="checkbox"/> ADEM	<input checked="" type="checkbox"/> Reactive astr...	



- All classifiers available assign our problem case to the pseudotumoural class, and we can reasonably suspect that, according to the MRS, this case is NOT a tumour but a pseudotumoural disease.

- The patient had, in fact, a multiple sclerosis plaque that mimicked a tumour.